

# PILONIDAL SINUS: A SIMPLE TREATMENT

By PETER H. LORD

H. N. SMITH RESEARCH FELLOW, ROYAL COLLEGE OF SURGEONS OF ENGLAND; CONSULTANT SURGEON, HIGH WYCOMBE

AND DOUGLAS M. MILLAR

LECTURER IN SURGERY, ST. GEORGE'S HOSPITAL, LONDON, S.W.1

THERE are three aspects to the problem of pilonidal sinus: the aetiology, the natural history, and the treatment.

This paper is concerned with the last of these, and with the details of our experience with the management of 33 patients using a new method of treatment.

Five of these patients were admitted to hospital; 3 for four days and 2 for one day. The rest were treated with purely out-patient procedures. As we held a pilonidal sinus clinic on Saturday morning, many of our patients did not lose a single day at work.

The treatment is based on our interpretation of the pathology of the established lesion.

## PITS

We have found that in all our patients there is at least one, but usually several, midline pits in the natal cleft. Usually one or more of these pits is larger and communicates with the underlying cavity. Many of the pits are very small and only just visible to the naked eye; they are easily missed, especially in the presence of inflammation.

In 1 patient we found 11 pits. In 28 patients who underwent treatment but who had never had previous excision, altogether 89 pits were found.

Although these pits have been previously recognized by some writers, they are completely ignored by many. In our view unless all the pits are excised the lesion may not heal, and if it does there is a considerable risk of recurrence.

These pits are lined with squamous epithelium. Their nature and their role in the aetiology of this condition are still being investigated.

## THE CAVITY

In the midline and deep to the pits is a cavity lined with granulation tissue. At least one of the pits communicates with this cavity. The cavity may contain a nest of hair.

Kooistra (1942), with a vast experience of pilonidal sinuses, has illustrated a cavity lined by squamous epithelium with hair follicles. We have not seen such a lesion in any of our cases.

## LATERAL AND MIDLINE ABSCESS AND TRACK

If a cavity becomes sealed and pus accumulates it may spread laterally to form a lateral abscess. If this bursts or is incised, a track or sinus is formed between the cavity and the lateral opening. This track is also lined with granulation tissue.

Alternatively the abscess may expand in the midline and form a secondary opening in the natal cleft. In every case the midline track ran cephalad from the pits and the cavity.

Nine patients had a lateral track. Eight patients had a midline track. Some of the tracks were more than 2 in. long.

## HAIR

In half our patients hair was found in the pilonidal sinus. We are of the opinion that no pilonidal sinus will heal permanently until all the hair has been removed.

## TREATMENT

1. **The Pits and the Cavity.**—Using local infiltration of 2–6 ml. of 1 per cent xylocaine with 1:200,000 adrenaline, the pits were excised down to the underlying cavity through a small elliptical incision.

We aim to remove as little normal skin as possible, less than  $\frac{1}{2}$  cm. to each side of the midline.

No attempt is made to remove the cavity as this is lined with granulation tissue. It has now been deroofed and can drain freely. Any hair within it is picked out with forceps and the cavity mopped clean.

**2. Lateral and Midline Tracks.**—The lesion will not heal unless all the hair has been removed, and hair may be lurking in lateral or midline tracks.

It can be removed by laying the tracks open, as advocated by Buie (1938) (*see also* Abraham and Cox, 1954), but this adds considerably to the magnitude of the procedure.

We have tried many methods for removing this hidden hair and have found the most effective to be a tiny 'bottle' brush with nylon bristles such as is used for cleaning electric razors.

The track is stretched with sinus forceps. The brush is then inserted and rotated. Hairs become

reserve supply with instructions that if there is bleeding he is to change the gauze and apply pressure by sitting on it. He is told to start daily baths with change of dressing after 36 hours. The cavity is *not* packed.

There are two minor points which we feel we should mention in describing our technique, although we attach no great importance to either of them.

First, in patients with bristly hair which grows quickly, we have found it convenient to avoid frequent visits for local shaving by destroying the hair follicles immediately around an excision with diathermy current using a short-wave epilation unit.

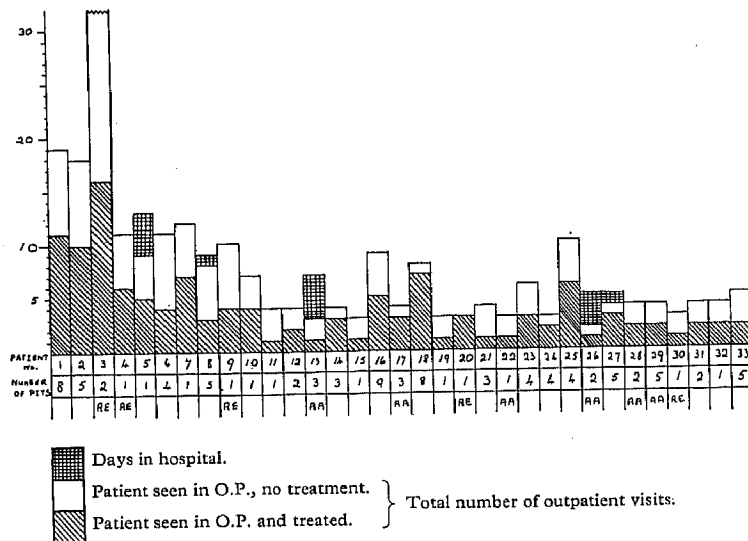


FIG. 1.—The histogram summarizes the management of 33 patients who presented with symptoms due to pilonidal sinus between 1 Jan., 1962, and 1 July, 1963. All except Case 3 were discharged apparently cured.

Patients are numbered 1-33 in the order in which they were first seen at the clinic.

RE = Recurrent after previous excision elsewhere.

AA = Patient presented with an acute abscess.

entangled in the bristles of the brush and are easily seen when the brush is withdrawn. This is repeated several times until there is no more hair.

We have sometimes found that a hydrogen peroxide washout has helped to loosen the hairs and clean out the cavity and track. It is essential that the track drains freely both ways—onto the surface and into the cavity. It is sometimes wise to excise a tiny disk of skin from around a lateral opening to help ensure good drainage.

**3. Shaving.**—We have several times seen hair actually growing down the track of a pilonidal sinus from the skin just around its opening. We therefore regard meticulous shaving for a centimetre around the edge of the excision wound as essential, and this is repeated at 2- or 3-week intervals until healing is complete.

A general shave of the whole area is desirable for reasons of hygiene and because strapping is used to hold the dressing in position.

It is, of course, well recognized that shaving alone will allow some pilonidal sinuses to heal.

**AFTERCARE**

The patient is sent home with a large gauze pack held in place by strapping. He is given a generous

Secondly, on one or two occasions we have used a specially sharpened cork borer passed over a probe to excise a track which was surrounded with dense fibrosis. We feel that this manœuvre may have accelerated healing.

**THE ACUTE ABSCESS**

Six of our patients presented with an acute abscess. Two of these patients (Cases 13 and 26) were admitted to hospital, given a general anaesthetic, and the pits were excised, the abscess draining freely in each case via this excision. They were each in hospital for 4 days. The 4 other patients (Cases 17, 22, 28, 29) had similar treatment as out-patients using local anaesthesia, with an equally satisfactory result.

**COMPLICATIONS**

Bleeding was troublesome in 2 patients: one came back to hospital and was admitted overnight (Case 27). The other called in his general practitioner.

Our only other complication so far has been delayed healing. Cases 1-9 were at the beginning of the series and in retrospect they had inadequate treatment in the first instance, either retained hair or loculation of pus.

Case 3 was very troublesome. She has been apparently healed on several occasions but with a

thin, weak scar into which hair has grown from surrounding skin causing a further breakdown. She is kept controlled only by repeated visits for local shaving. Her hair is very fine. Depilation has been attempted but was unsuccessful.

Case 18 was slow to heal. He had a truly remarkable amount of hair in his sinus and several attempts were made before this was all removed.

### RESULTS

Forty patients attended our pilonidal sinus clinic during the 18 months from 1 Jan., 1962, until 1 July, 1963.

Five of these were symptomless and were therefore not treated.

One deferred treatment until he had passed an examination and has not been seen since.

One had a granuloma following treatment elsewhere for pilonidal sinus. This eventually responded to shaving and AgNO<sub>3</sub> cautery.

Thirty-three were treated and all but 1 are soundly healed and have been discharged.

The treated patients have been numbered in the order in which they first attended (*Fig. 1*). During the first six months of the series (*Cases 1-9*) our ideas of management were still not crystallized. This is reflected in the larger number of visits that these patients made. In the latter part of the series, when the above regimen was strictly applied, 24 patients made a total of 107 visits, an average of less than five visits each.

### FOLLOW-UP

All the patients were seen again recently. The longest follow-up is 2 years, the shortest 6 months. All are symptom-free and with the exception of *Case 3* all have mobile, firm, linear scars without induration or pits.

### SUMMARY

All sinuses heal unless something keeps them open. Pilonidal sinuses are foreign-body sinuses in which the foreign body is hair. If the hair is removed and free drainage allowed, the sinus will heal. Midline pits have been found in association with a pilonidal sinus and it is suggested that these must be removed to avoid recurrence.

A method is described of achieving these objectives by simple out-patient procedures and the results are tabulated of 33 patients treated in this way with apparent cure in 32.

**Addendum.**—Since this paper was submitted a further 48 patients have been treated by the above method with results which are similar in every way to those reported.

### REFERENCES

- ABRAHAMSON, D. J., and COX, P. A. (1954), *Ann. Surg.*, **139**, 341.  
 BUTE, L. A. (1938), *Practical Proctology*. Saunders: Philadelphia.  
 KOOISTRA, H. P. (1942), *Amer. J. Surg.*, **55**, 3.